

Reviews on the use of the "Aquatone-02" device in the treatment of degenerative osteochondrosis.

Sochi. "Akvaloo" wellness center.

Sergey Kozlovsky, neurologist, reflexologist.

e-mail: dockozlovsky@inbox.ru. www.dockozlovsky.ru.

8-918-4072139

Patient M, age 63, osteoarthritis, arthritis, disseminated osteochondrosis of the spine.

Treatment was carried out with the "Aquatone-02" device, other therapeutic methods were not applied. The device was used in mode 2, during 2 sessions per day for 15 minutes. The effect was produced on the transition between the lumbar spine and sacrum.

For diagnosis, the infrared camera TV 04 KST. The compression at the nerve root can lead to inflammation and increased temperature, which is recorded by the program.

Diagnostic images of the lumbosacral junction and hip joint before and after treatment are shown in Figures 1 and 2.

Fig. 1. Diagnostic image of sacrum and hip joint before treatment.

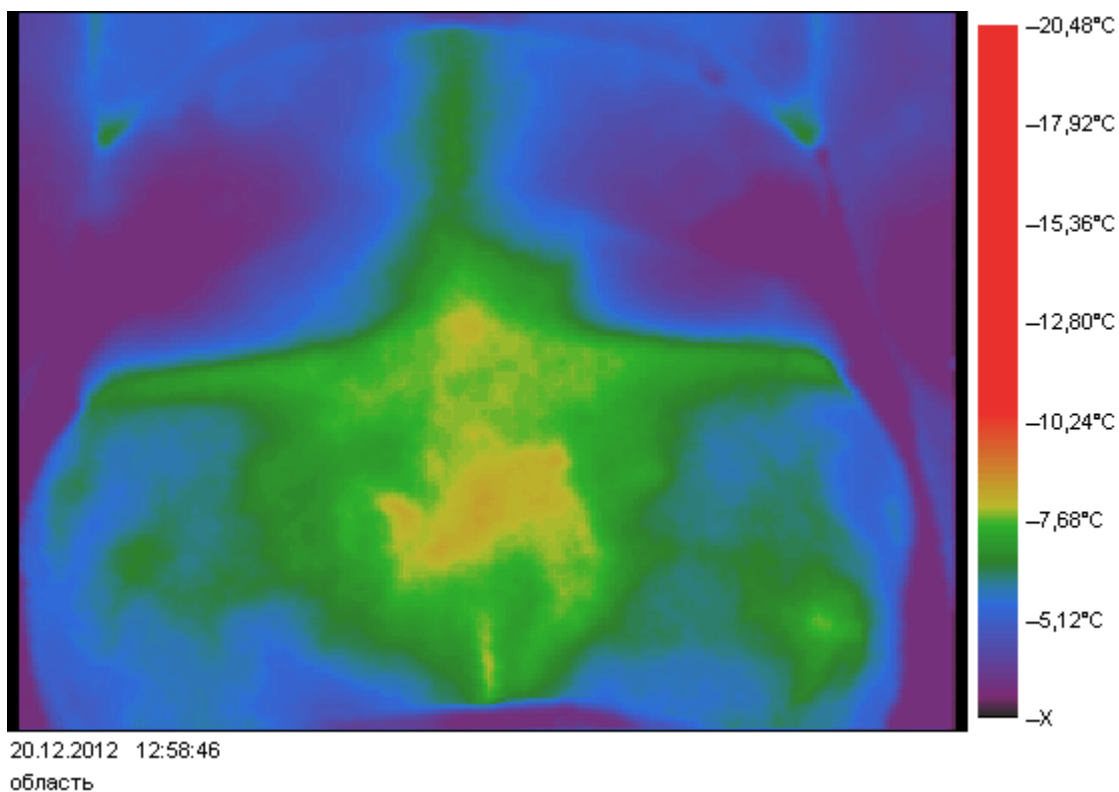


Fig. 2. Diagnostic view of the sacrum and the joint after 6 treatment sessions with the "Aquatone-02" device.

After six sessions with "Aquatone-02" unit was observed reduction of swelling and inflammation in the lumbosacral region, the patient experienced reduced pain, improved mobility in the lumbosacral area.

The "Aquatone-02" device demonstrated a significantly higher efficiency compared to previous physiotherapy techniques used physical therapy. For example, 12 or more therapy sessions with magnetic therapy, or electrophoresis demonstrated similar results.